



Dossier 11

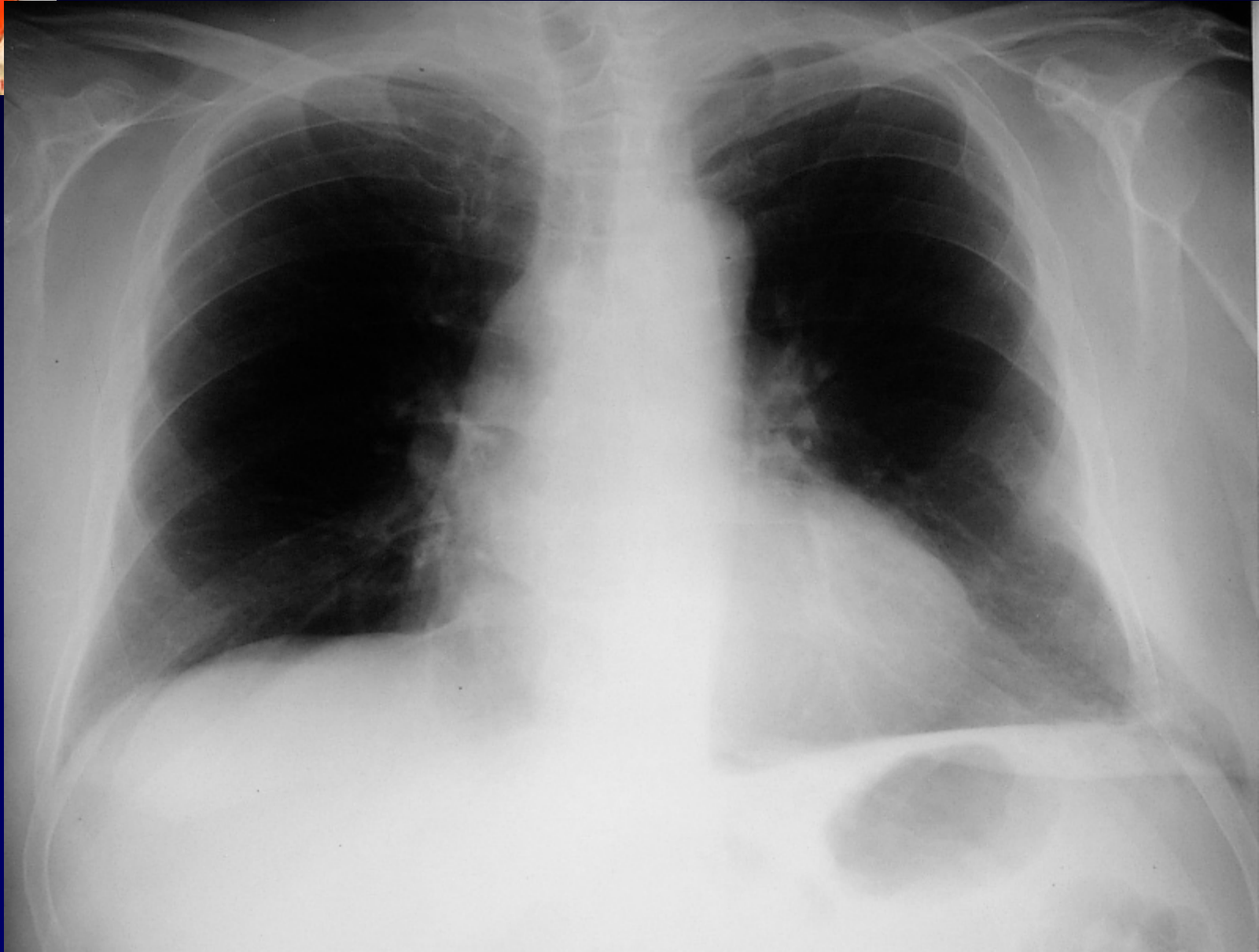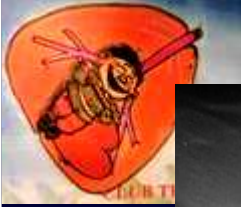E. MADEUF

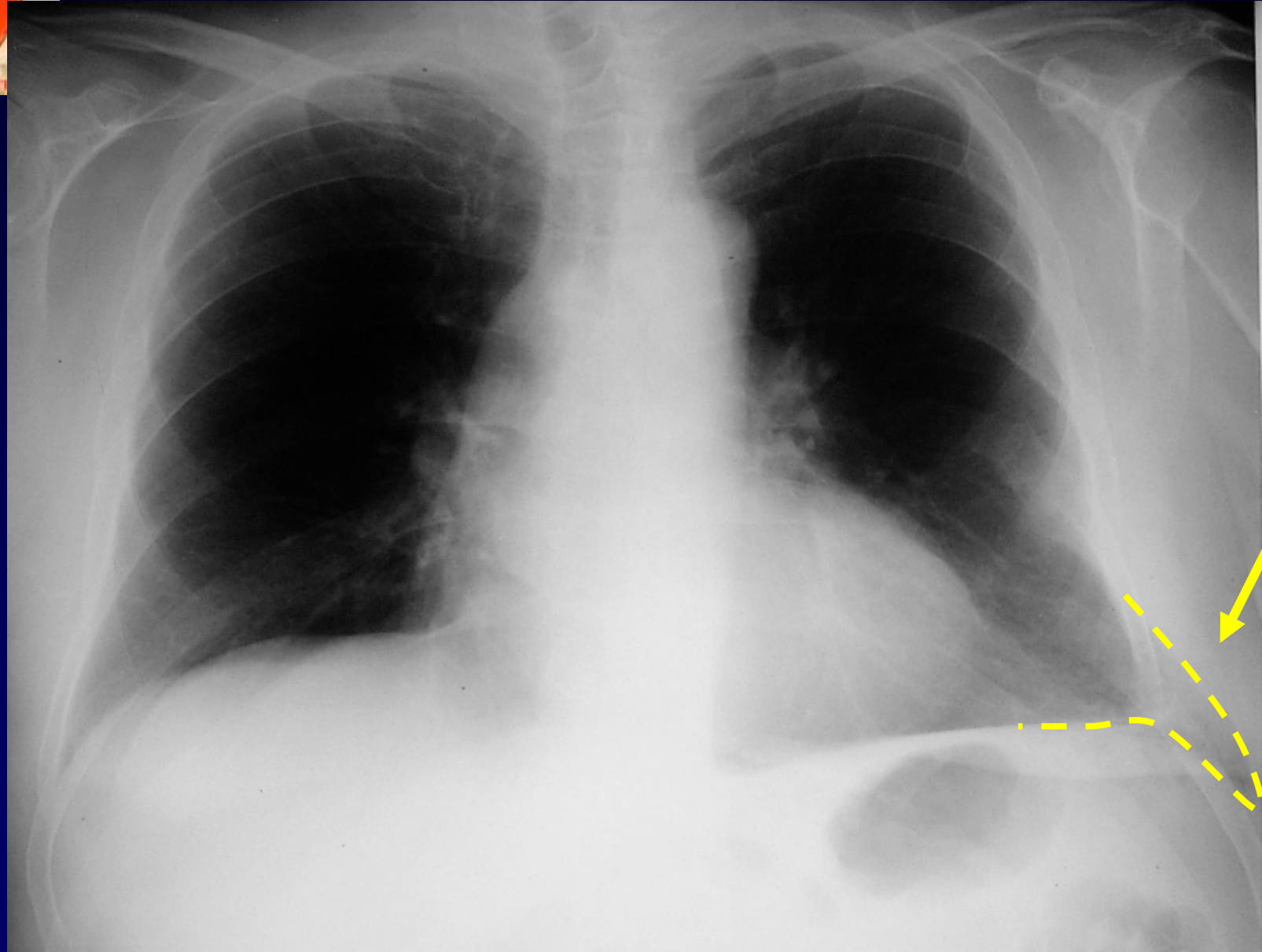
M. EL HAJJAM

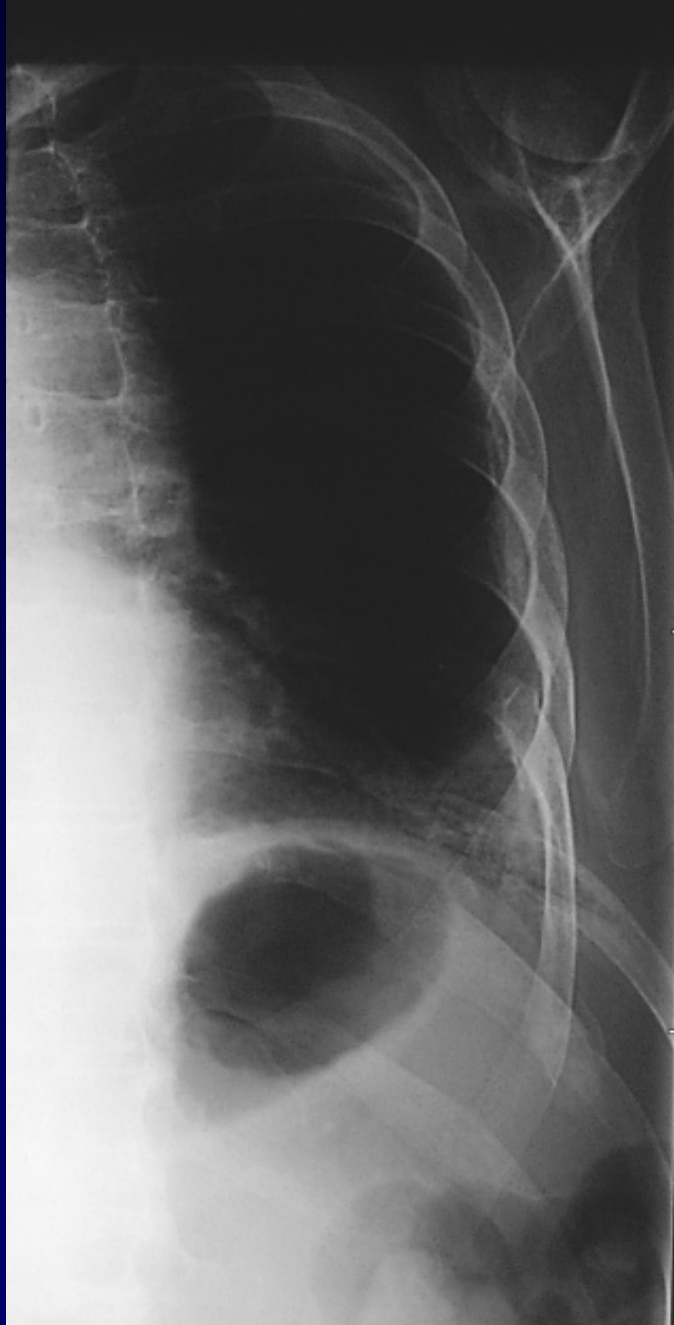
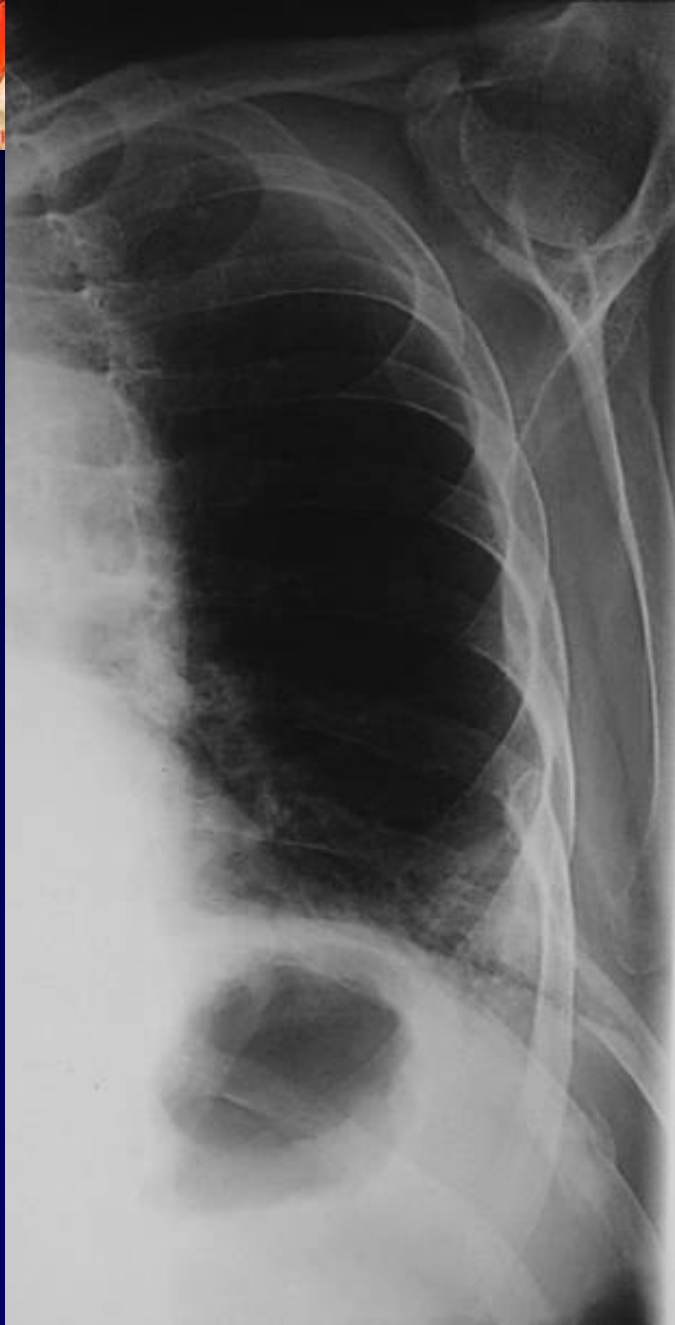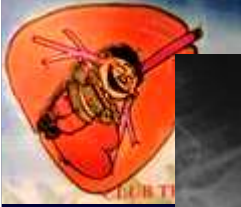Homme de 70 ans

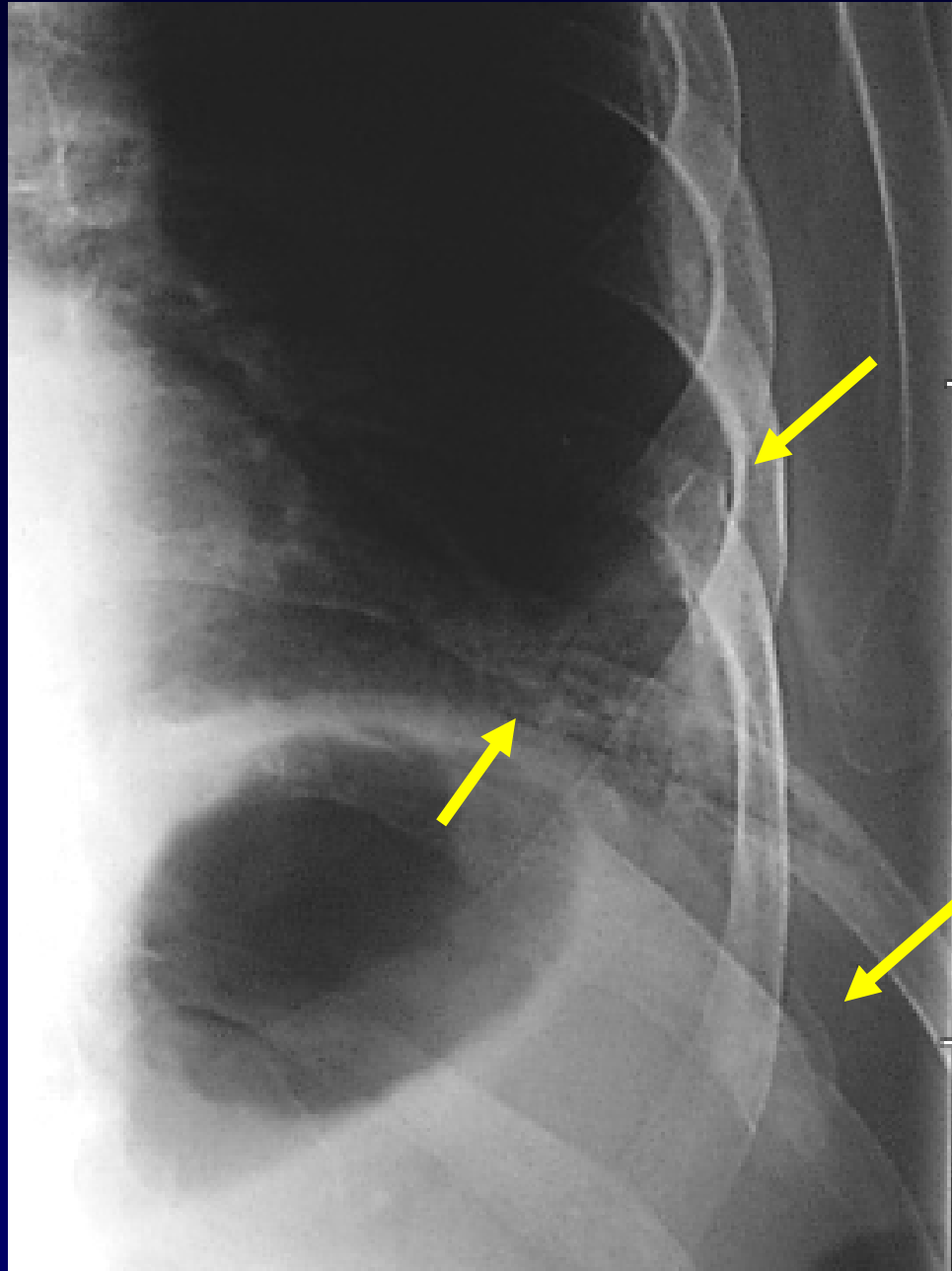
ATCD de traumatisme costal gauche

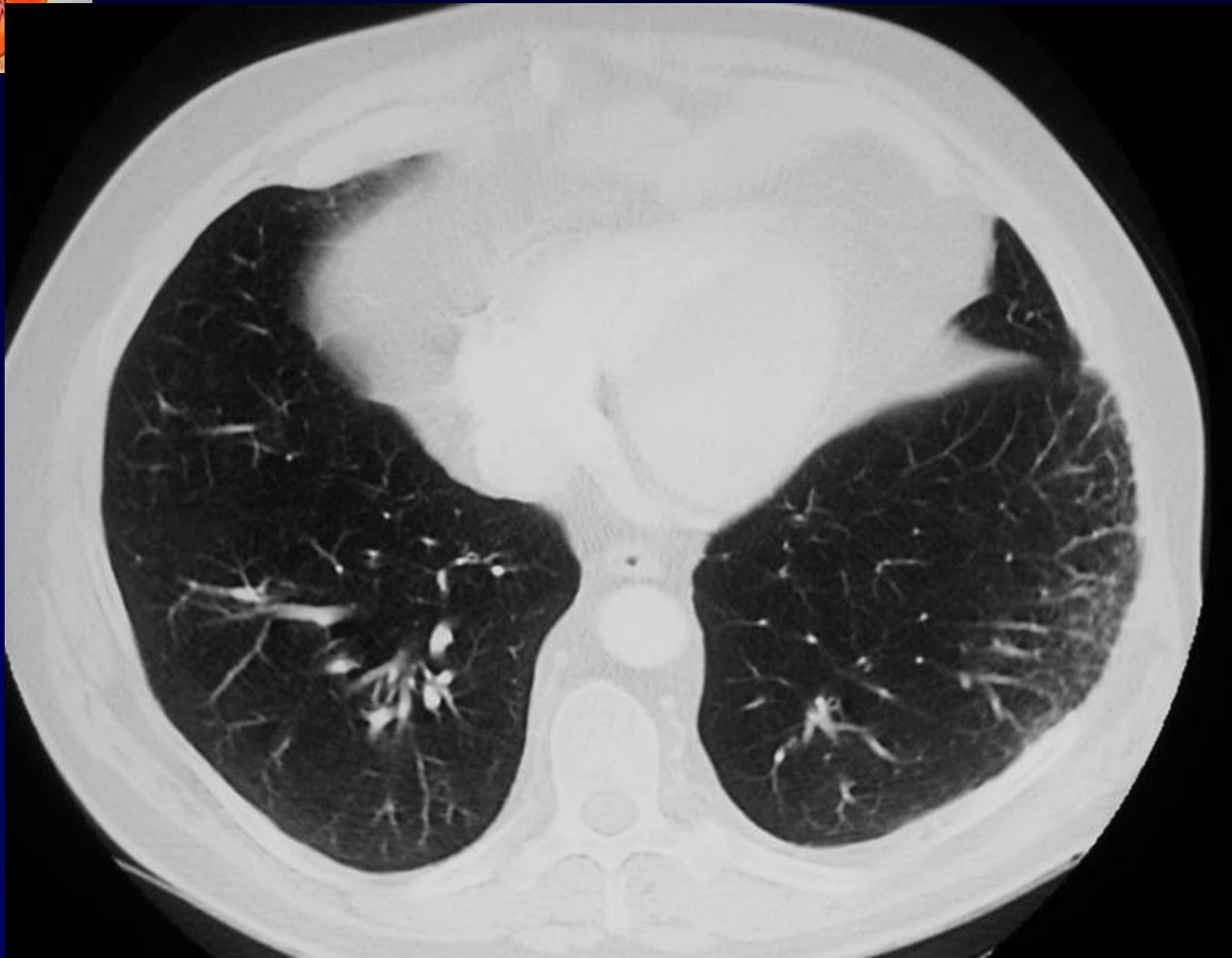
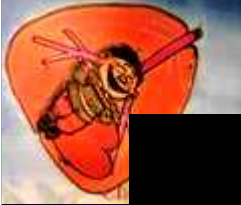
Voussure basi-thoracique gauche suite à un effort de toux, 4 mois après le traumatisme.

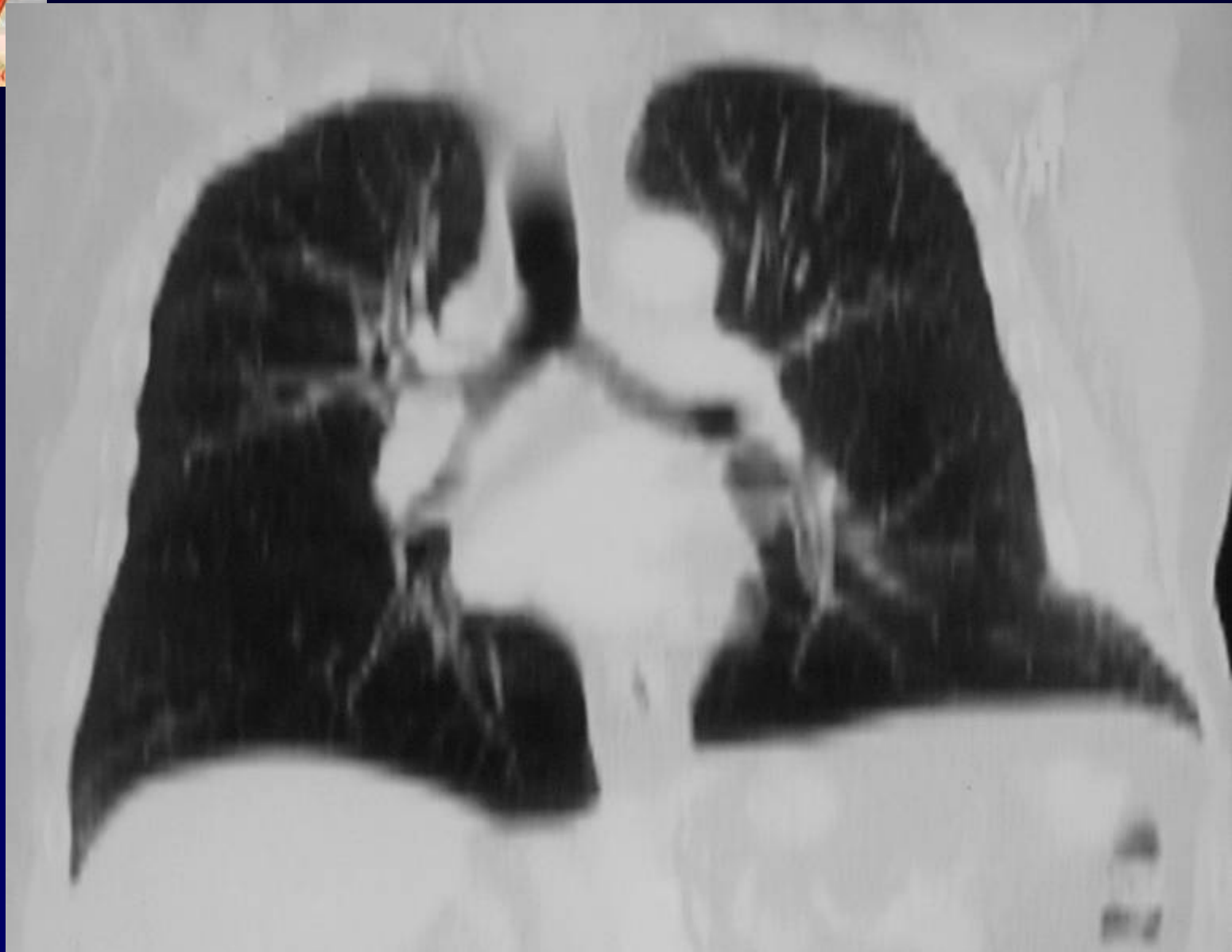
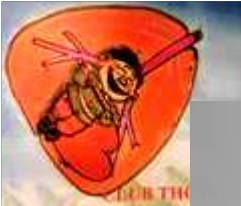
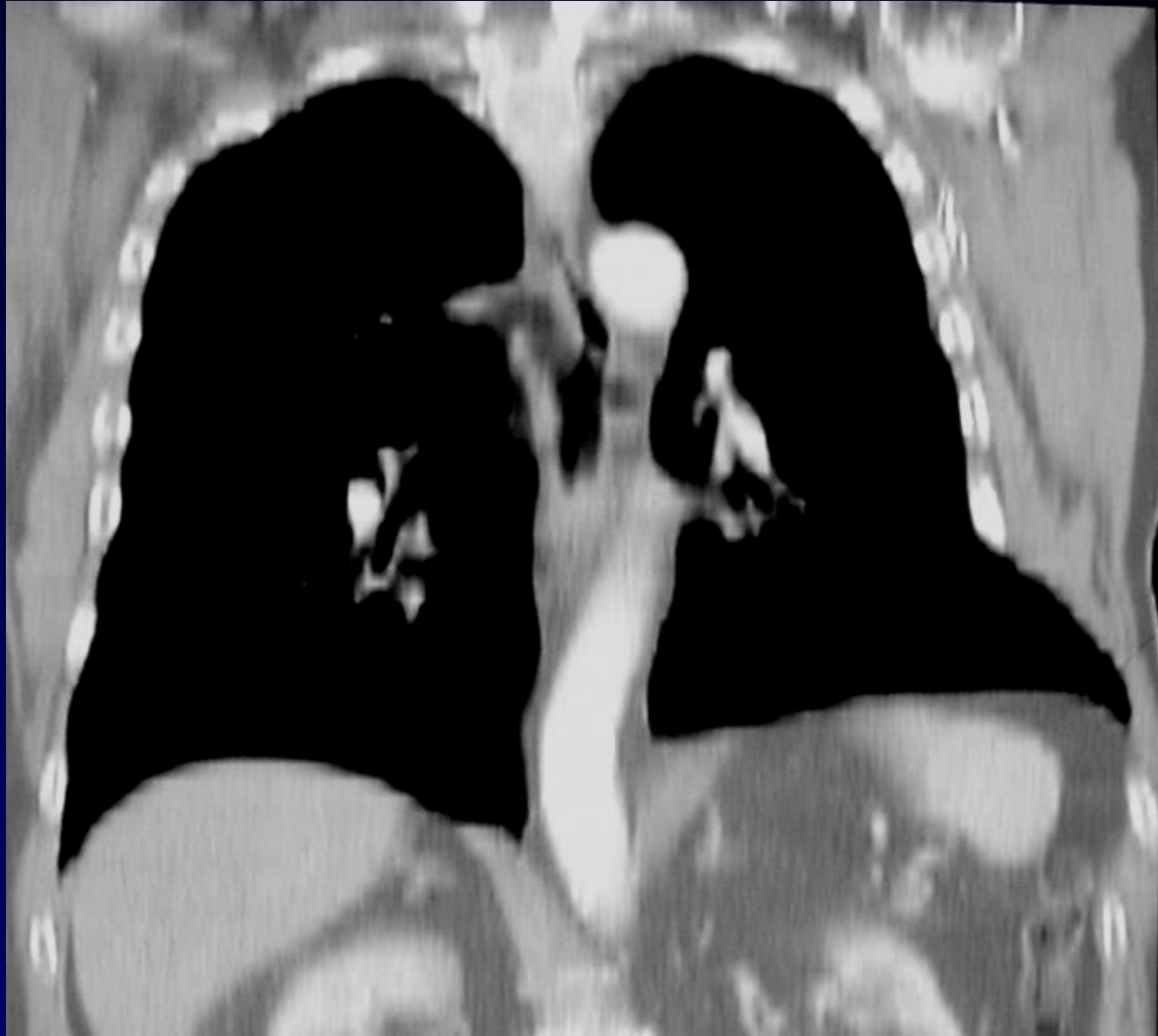








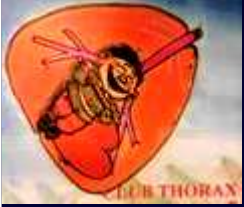





Diagnostic ?



Diagnostic

Fractures costales consolidées

Hernie pulmonaire gauche

post-traumatique

Codage : Paroi - Poumon - Traumatique